

## Case report

## Atypical presentation of laryngeal tuberculosis in a pediatric patient

Chelsea Obourn, Behrad Aynehchi\*, Boris Bentsianov

Department of Otolaryngology, State University of New York Downstate Medical Center, Brooklyn, NY, USA

## ARTICLE INFO

## Article history:

Received 2 January 2012

Received in revised form 6 February 2012

Accepted 8 February 2012

Available online 6 March 2012

## Keywords:

Pediatric otolaryngology

Otolaryngology

Infectious diseases

Laryngology

Tuberculosis

## ABSTRACT

Laryngeal tuberculosis is uncommon and most often associated with a primary lung infection in immunocompromised adults. We describe an atypical case in a pediatric patient with a relatively rapid onset and no history of travel or exposure to high-risk settings. Despite the unusual presentation and relative lack of familiarity with procedural guidelines in managing this uncommon and capricious disease by otolaryngologists in developed countries, reporting is mandated at multiple governmental health department levels. Consequently, this contagious entity must be considered in the interest of avoiding untoward outcomes for not only the patient, but the public as well.

© 2012 Elsevier Ireland Ltd. All rights reserved.

## 1. Introduction

Approximately 1 million children are affected with tuberculosis (TB) worldwide, with those from developing countries carrying the heaviest burden [1]. Approximately 21–44% of pediatric TB cases involve extrapulmonary sites, most commonly the cervical lymph nodes [1]. Laryngeal TB (LTB) has dwindled from 25% of all TB cases at the beginning of the 20th century to only 1%, mainly due to the advent of antimicrobials, improvements in living standards and widespread prevention programs [2]. We present a case of atypical LTB in a pediatric patient with an isolated rapid onset dysphonia and no history of immunosuppression or high-risk travel.

## 2. Case report

A 15-year-old girl presented hoarseness that had developed over the course of a week and remained stable thereafter for about 8 months. The patient denied dysphagia, odynophagia, cough, hemoptysis, fever, chills, sick contacts, night sweats or weight loss. There was no recent travel history and she was born and raised in New York City. She reported a history of a positive Purified Protein Derivative (PPD) when she was young, with a course of medical treatment. Past medical history was significant only for asthma.

The patient's voice was noted to be weak and breathy without stridor. The remainder of the physical examination was normal.

Notably, the chest was clear to auscultation bilaterally with no cervical lymphadenopathy. Flexible fiberoptic laryngoscopy performed in the office showed non-specific findings of fullness of the bilateral false vocal cords along with mucosal irregularities (Fig. 1).

The patient was brought to the operating room, where direct laryngoscopy with biopsy, rigid bronchoscopy and rigid esophagoscopy were performed. Findings on intraoperative examination included a friable right cricoarytenoid complex and false vocal cord with ecchymotic changes. Both vocal cords featured friable fullness in the posterior aspects as well (Fig. 2). There were no subglottic lesions and esophagoscopy was unremarkable. Biopsies were taken and pathology of the tissue revealed extensive necrotizing granulomatous inflammation. Histopathologic evaluation was positive for acid-fast bacilli.

Following the diagnosis of LTB, hospital infection control was notified, the patient was admitted an isolation unit and an anti-tuberculin regimen was initiated. Chest radiography revealed cavitory lesions in the apices of both lung fields.

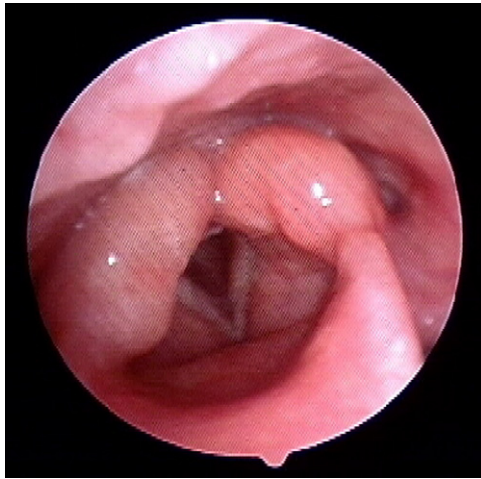
## 3. Discussion

In contrast to our patient, LTB shows a male predominance, most commonly affecting those in their fifth to sixth decades [2,3]. An accompanying history of heavy tobacco and ethanol use along with some form of immunosuppression is also usually present. Immigrants from endemic areas, including Sub-Saharan Africa and Asia, are at increased risk [2]. The only risk factor present in our patient was a prior history of a positive PPD with subsequent treatment.

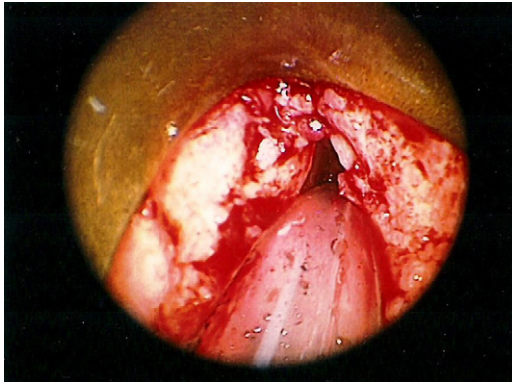
The pathogenesis of LTB includes primary and secondary forms. Primary infection (more rare) is thought to occur from directly

\* Corresponding author at: SUNY Downstate Department of Otolaryngology – Head and Neck Surgery, 450 Clarkson Ave., Box 126, Brooklyn, NY 11203, USA. Tel.: +1 718 270 1638; fax: +1 718 270 3924.

E-mail address: [baynehchi@gmail.com](mailto:baynehchi@gmail.com) (B. Aynehchi).



**Fig. 1.** Flexible fiberoptic examination showing fullness of the bilateral false vocal cords and mucosal irregularity.



**Fig. 2.** Direct laryngoscopy showing friable lesions involving cricoarytenoid complexes and true and false vocal cords.

inhaled inoculation [4]. Secondary infection is a result of direct spread from a primary pulmonary infection as well as hematogenous dissemination [2,4]. The current literature notes an absence of pulmonary involvement in about 6% of cases of LTB, with more lesions observed in the anterior larynx due to hematogenous dissemination [2].

LTB most commonly presents with mild progressive dysphonia, seen in about 85% of cases [5]. This symptom in our patient developed relatively more acutely. In contrast to adults, children with LTB show higher rates of airway compression and stridor [6]. Systemic symptoms and hemoptysis are less common with LTB [5].

It is important to note that there are no specific pathognomonic features of LTB on examination. As in our patient, findings on fiberoptic laryngoscopy are varied and can include edema,

hyperemia, ulcerative lesions, nodules, exophytic masses and sometimes obliteration of anatomical structures [3]. This ambiguity in physical features in the setting of unexplained laryngeal symptoms underscores the need for a high degree of vigilance and low threshold for direct examination with biopsy specimens when dealing with in order to avoid consequences of misdiagnosis and delays in treatment. By decreasing incidence, laryngeal lesions involve the true vocal cords, epiglottis, false vocal cords, ventricles, arytenoids, posterior commissure and subglottic area [3]. Owing to these non-specific findings on gross examination, histologic confirmation of a diagnosis of LTB upon identification of caseating granulomas along with mycobacterium on Ziehl–Neelsen (acid-fast) histochemical staining is vital [3,7].

Once the diagnosis of TB is made, reporting to the health department of the county in which the patient resides (in our case, New York City Department of Health) is mandated. Treatment for pediatric patients typically includes 6 months of the 4-drug regimen rifampin, isoniazid, pyrazinamide and ethambutol [6]. Steroids may also be helpful when there are signs of airway involvement [6].

Due to the paucity of cases of laryngeal tuberculosis, many otolaryngologists may not be familiar with the presentation and management of this entity. In efforts to avoid untoward outcomes for the patient, healthcare workers and public at large, it is important for the clinician to be familiar with this contagious disease.

Verification and approval from the appropriate institutional research oversight committee was obtained for this case report.

#### Conflict of interest statement

None to disclose.

#### Funding source

None to disclose.

#### References

- [1] J. Nelson, C. Wells, Global epidemiology of childhood tuberculosis, *Int J Tuberc Lung Dis* 8 (2004) 636–647.
- [2] P. Rizzo, M. Da Mosto, M. Clari, P. Scotton, A. Vaglia, C. Marchiori, Laryngeal tuberculosis: an often forgotten diagnosis, *Int J Infect Dis* 7 (2003) 129–131.
- [3] Y. Smulders, B. De Bondt, M. Lacko, A.L. Hodge, J.K. Kross, Laryngeal tuberculosis presenting as a supraglottic carcinoma: a case report and review of the literature, *J Med Case Rep* 3 (2009) 9288.
- [4] A. Mehndiratta, P. Bhat, L. D'Costa, A. Mesquita, N. Nadkarni, Primary tuberculosis of the Larynx, *Indian J Tuberc* 44 (1997) 211–212.
- [5] L. Barbosa de Sa, R. Meirelles, C. Atherino, J. Fernandes, F. Ferraz, Laryngo-pharyngeal tuberculosis, *Rev Bras Otorrinolaringol* 73 (6) (2007) 862–866.
- [6] K.K. Gregg, A.K. Detjen, P. Goussard, R. Gie, Laryngeal involvement in two severe cases of childhood tuberculosis, *Pediatr Infect Dis J* 28 (December (12)) (2009) 1136–1138.
- [7] S. Verma, S.K. Verma, Sanjay, Laryngeal tuberculosis clinically similar to laryngeal cancer, *Lung India* 24 (2007) 87–89.